



This publication is the joint copyright of
 The International Circumcision Forum © Inter-Circ 2014-2020 and
 The Circumcision Helpdesk™ © The Circumcision Helpdesk™ 2000-2020
 All rights reserved.



A Glossary of Terms

Relating to Circumcision, the Genitals & Urinary Organs



Copyright Notice

This publication is the joint copyright of
The International Circumcision Forum © Inter-Circ 2014-2020 and
The Circumcision Helpdesk™ © The Circumcision Helpdesk™ 2000-2020
All rights reserved.

Any redistribution or reproduction of part or all of the contents in any form is prohibited other than for the following purposes:

- Printing or downloading this document to a local hard disk for your personal and non-commercial use (note that Cloud storage is not permitted),
- Copying the latest version of the entire document, electronically or in printed form, to individual third parties for their personal use. No charge shall be made and Inter-Circ: The International Circumcision Forum shall be identified as the source of the material (Doctors, their Clinics and other medical staff may distribute this document to their patients without our explicit consent, as if they were non commercial organisations),
- Providing a standard hyperlink from your personal web site or blog to the latest version of this document subject to it opening in a new browser window or tab, complete with the Inter-Circ identity in the URL line of the browser,
- Quoting parts of this publication for scholarly, academic or review purposes provided the source is acknowledged as above.

For all commercial organisations: you may not distribute or exploit the content of this document, nor may you transmit it or store it in any other website or other form of electronic retrieval system without our explicit written permission.

Written requests for this type of use should be directed to:
inter-circ+owner@groups.io

Recommended links

Inter-Circ is not the only publisher of reliable information regarding circumcision. The following sites are recommended as they are based on medically correct information. Inter-Circ has no control over the content of external sites and does not vouch for their accuracy or continued availability.

Inter-Circ: The International Circumcision Forum
<https://groups.io/g/Inter-Circ>

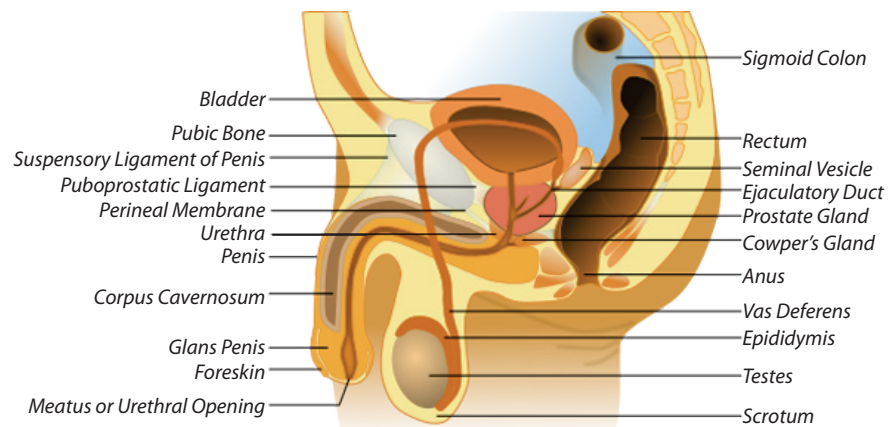
The Circumcision Helpdesk™ Web Sites
<http://www.circumcisionhelpdesk.org>
<http://www.circlist.com>

Professor Dr Morris's Web Site
<http://www.circinfo.net>

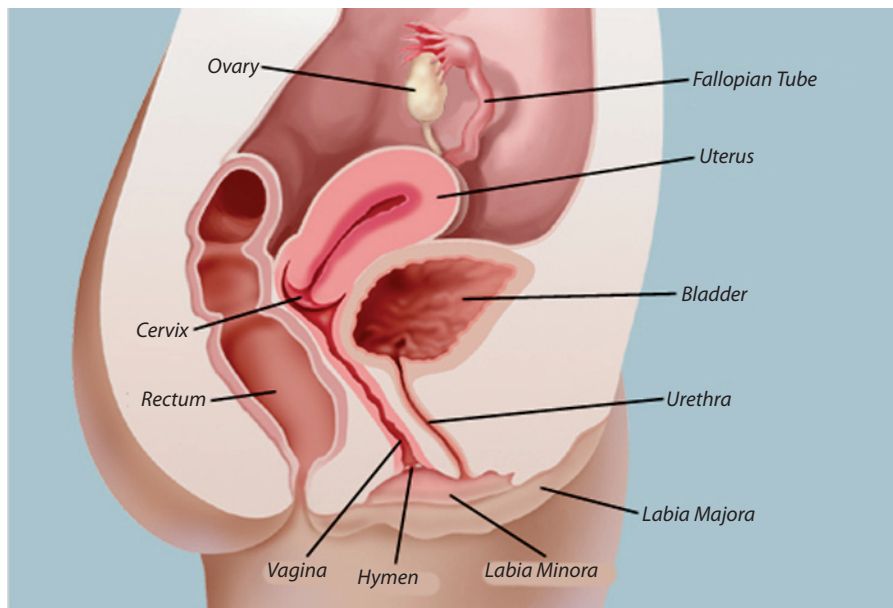
The Circumcision Fact Web Site
<http://www.circfacts.org>

The Circlist Web Site
<http://www.circlist.com>

Male Genital Organs



Female Genital Organs



These two diagrams are reproduced from Wikipedia, with minor amendments, under the Creative Commons license.

A Glossary of Terms

Relating to Circumcision, the Genitals & Urinary Organs

Authors

Inter-Circ Moderation Team
in conjunction with **The Circumcision Helpdesk™**

Medical Advisor

John Murray M.D.

Fourth Edition

Last updated January 2020



Inter-Circ: The International Circumcision Forum

is a volunteer-run pro-circumcision group. The purpose of the group is to make known the benefits of circumcision, to debate topical issues related to the subject and to offer advice both pre- and post-circumcision.

The Inter-Circ forum is located at:

<https://groups.io/g/inter-circ>

Disclaimer

Whilst every effort has been made to ensure the accuracy of the information contained within this publication, it is intended as a guide only and not as a source of complete or totally indisputable information.

This glossary does not constitute 'medical advice' and is not intended as a substitute for the advice of your medical practitioner.

Introduction

Readers may not be familiar with some of the terminology, relating to circumcision and the urino-genital organs, that is used on Inter-Circ and other discussion groups or web sites, which provide information regarding male circumcision. This glossary aims to provide definitions and information about many such terms.

Slang or colloquial terms are given in ***Bold Italic***.

Terms which are further defined are shown in *italic* whenever they are referenced.

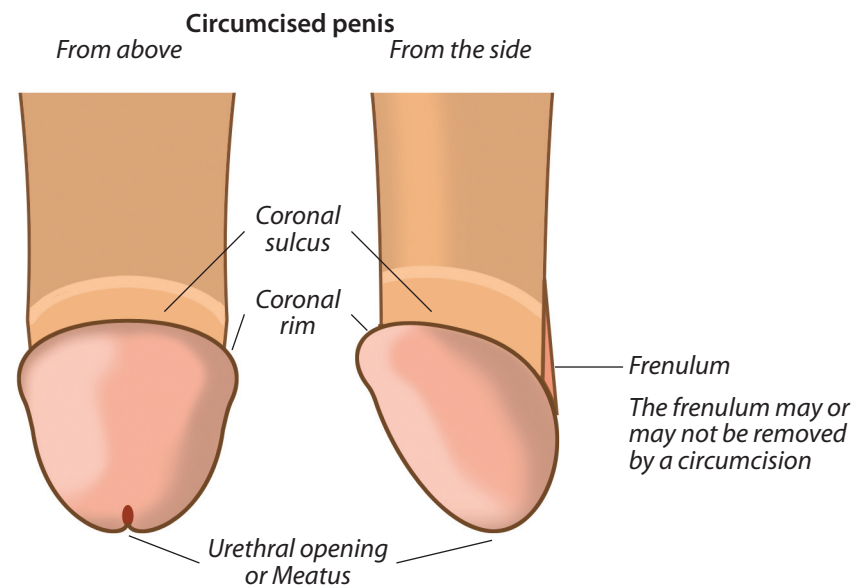
At the end of the guide there are drawings of the penile anatomy, together with the male and female genital organs, which may help in any discussion of circumcision. There are also links to recommended web sites which offer further useful information.

The *Circlist web site* (<http://www.circlist.com>) is a particularly valuable source of additional information, including illustrations of some of these terms.

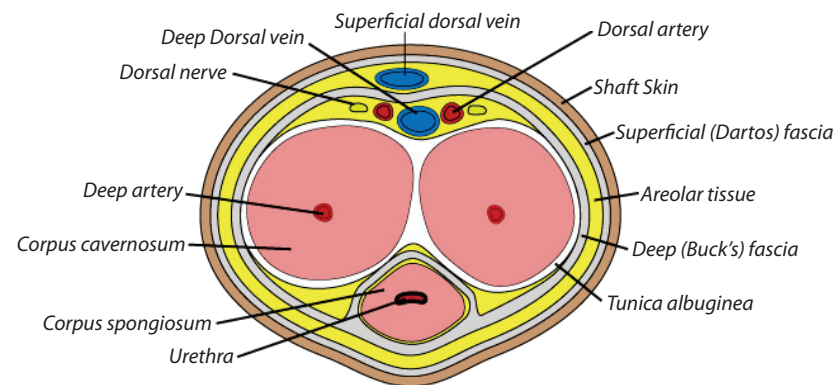
Spellings are in accordance with the standards of British and International English. North American spellings replace the 'ae' and 'oe' diphthongs in words such as 'Oedema' and 'Haemorrhage' with a single 'e' – eg 'Edema'.

Contents

Glossary	Page 3
Circumcised and uncircumcised penises.....	Page 26
Cross-section of penis shaft	Page 27
Male Genital Organs	Page 28
Female Genital Organs	Page 28
Recommended links	Page 29



Cross-section of penis shaft

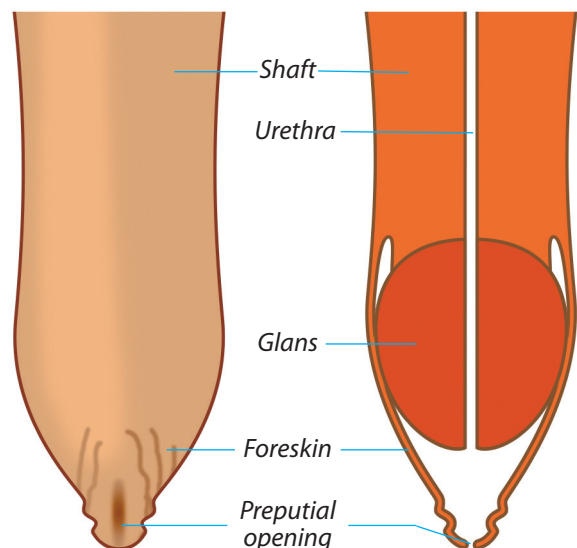


This diagram is reproduced from Wikipedia, with minor amendments, under the Creative Commons license.

Circumcised and uncircumcised penises

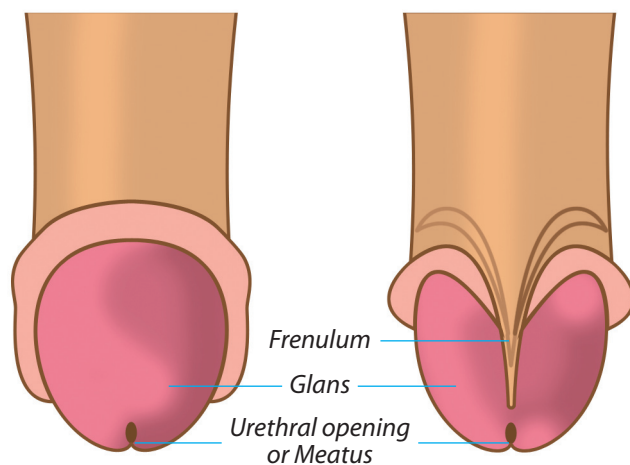
Uncircumcised penis
with foreskin intact

Section through an
uncircumcised penis



Uncircumcised penis with foreskin retracted
From above

From below



Glossary

Adhesions See *Synechia*

Age of Consent, Age of Sexual Consent The age at which a person can validly consent to a sexual act with another person.

This varies from jurisdiction to jurisdiction and is usually lower than the *age of majority* (legal adulthood).

Age of Majority The age at which a person legally becomes an adult. This varies from jurisdiction to jurisdiction, and is mainly 18 or 21.

Age of Medical Consent The age at which a person can give valid personal *informed consent* to medical procedures and does not require parental consent.

This varies from jurisdiction to jurisdiction and is usually lower than the *age of majority* (legal adulthood). It is not necessarily the same as the *age for sexual consent* and may be earlier in some circumstances.

Ampallang A hole piercing the *glans* transversely, in which a *bar-bell* or other object is worn.

Anterior Towards the front. Opposite of *Posterior*.

Anus The *posterior* opening of the alimentary canal, through which excrement is ejected. (See diagram on Page 28.)

Apadravya A hole pierced through the *glans* from *dorsal* to *ventral* surfaces (usually from the centre of the upper surface of the *glans* and emerging at the *frenulum*), in which a *bar-bell* or ring is worn.

Aposthia The condition of being naturally without a *foreskin*. Each year a few boys are born without any foreskin or with such a very short foreskin that it doesn't cover any of the *glans* when *flaccid* and thus although *uncircumcised* they have the appearance and all the benefits of being *circumcised*.

Arse, Ass Slang terms for the buttocks, rump or bottom (of any animal). Obsolete in polite use.

Atrophy Wasting away of (part of) the body.

Balanitis Inflammation of the *glans*. It may be caused by trauma, irritants or infection.

Infective balanitis is commonly caused by bacteria or fungi (yeasts) which thrive in the warm, moist, dark conditions under the *foreskin*.

Poor hygiene, retained soap or detergent, retained *smegma*, retained *urine* or inadequate drying may cause an irritant balanitis.

Although strictly meaning only inflammation of the *glans*, the term is commonly used to cover inflammation of the *glans* and *foreskin* – a condition more correctly termed *balanoposthitis*.

Recurrence of balanitis is prevented by *circumcision*.

Balanitis Xerotica Obliterans (BXO) See *Lichen Sclerosus et Atrophicus*.

Balanoposthitis Inflammation of the *glans* and *foreskin*. More commonly referred to simply as *balanitis*.

Balanus (Latin) See *Glans*.

Ballooning A condition caused by *phimosis* in which urine cannot escape from the tip of the foreskin as fast as it is fed into it from the bladder. The foreskin thus swells up with the pressure of the urine inside it and the infant usually cries with the resultant pain.

The backward pressure placed on the bladder can cause damage to that organ and can also put additional strain on the kidneys which, especially in an infant, can easily be permanently damaged.

Balls A slang term for the *testicles*.

Banjo String A slang term for the *frenulum*.

Bar-Bell A short rod of precious metal, stainless steel or titanium with a ball at each end, one of which can be unscrewed for insertion into a body piercing such as an *ampallang*, *apadravya* or *dydoe*.



Barzel

Barzel (See photo.) The traditional Jewish shield through the slot of which the infant's *foreskin* is pulled to hold it in place to be cut off in a *Brit Milah*.

Basal Circumcision A method of *circumcision* by which a strip of skin is removed from all around the *penis* at its base. When the two edges are stitched together the scar line becomes hidden in the pubic hair. The whole of the *foreskin* is actually retained, being in a state of permanent retraction.

This method, which is favoured in Japan, should not be used in cases of *phimosis* since the tight *phimotic ring* will be retained, but positioned on the shaft which it may compress giving an hour-glass appearance to the penis, or even closing the *urethra*.

Bladder An organ between the *kidneys* and the *penis* which stores *urine* until it is ready to be voided. (See diagrams on Page 28.)

Blow Job A slang term for oral sex. See *Fellatio*.

Brit Milah (Bris) The religious *circumcision* of a Jewish boy on the 8th day (counting the day of birth as the first day).

Buck's Fascia Part of the inner structure of the *penis* (See diagram on Page 27). It is the Buck's Fascia, not the shaft skin, that holds the innermost components of the penis in place. Care is taken during a *circumcision* to ensure that the Buck's Fascia is not cut.

Varicocele (pronounced 'variko-seal'). Varicose condition or dilation of the veins of the spermatic cord.

Vas Deferens (Latin for sperm duct). The tubes in the spermatic cord which carry *semen* from the *testicles* to the prostate. (See diagram on Page 28.)

Vasectomy A (usually very effective) form of birth control in which the *vas deferens* on each side is cut and tied in a minor operation, usually done only when a man does not intend to father children; a reversal operation is sometimes possible but not always successful.

Ventral A medical term meaning 'on the lower surface'; or 'in the lower part'. Opposite of *Dorsal*.

Vulva The external sexual parts of the female. These include the *labia* and *clitoris*.

Wank To *masturbate*, particularly in the male.

Womb See *Uterus*.

Z-Plasty One of several forms of *preputioplasty* used to relieve *phimosis*. It has the disadvantage of leaving a visible scar on the end of the *foreskin*. The resulting scar may tighten over time, creating another *phimosis*.

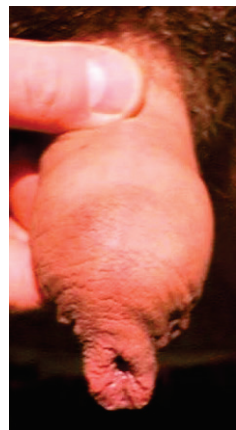
Topical Applied to the external surface, as for example the topical anaesthetic ointment *EMLA™ Cream*.

Tumescence The process of becoming swollen or inflated. Erection of the *penis*.

Tunica Albuginea (Latin) A membrane in the *penis*. (See diagram on Page 27.)

Tunica Vaginalis (Latin) A membrane in the *scrotum*.

Tyson's Glands These are secretory glands which are symmetrically located on either side of the *frenulum*. They produce an oily lubricant for the *foreskin*.



Uncircumcised

Uncircumcised (See photo.) The original state of the *penis* before *circumcision*, with *foreskin* covering the *glans*.

Uncut *Uncircumcised*.

Ureter The tubes through which *urine* passes from the *kidneys* to the *bladder*. Do not confuse with the *urethra*.

Urethra The tube in the *ventral* portion of the *penis* through which *urine* and *semen* pass. (See diagrams on Pages 26 - 28.)

Urinary Meatus See *Meatus*.

Urine Liquid waste carrying toxins, *urea* and excess water from the *kidneys* out of the body via the *bladder* and *penis*.

Urologist A doctor specialising in the diseases and problems of the male urinary system and genitals.

They usually also deal with problems of the female urinary system, whilst a *Gynaecologist* deals with their genital organs.

Uterus The uterus is a pear-shaped, muscular reproductive organ from which women menstruate and where a normal pregnancy develops. The uterus is normally about the size of a woman's fist. It stretches many times that size during pregnancy. It is sometimes referred to as the womb. (See diagram on Page 28.)

During sexual arousal, the lower end of the uterus lifts toward the abdomen, which creates more space at the end of the *vagina*.

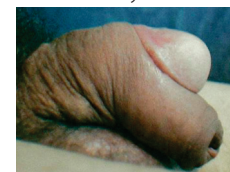
Vagina The vagina is the stretchable passage that connects a woman's external sex organs with her *cervix* and *uterus*. (See diagram on Page 28.) The vagina is a tube with walls of wrinkled tissue that lay against one another. The walls open just enough to allow something to go in the vagina, like a tampon, finger, or *penis*.

The vagina is 2 – 4 inches long when a woman is not aroused and 4 – 8 inches long when she is sexually aroused.

The vagina has three functions: To allow menstrual flow to leave the body; to allow sexual penetration to occur (either by hand, sex toy, or penis); to allow a fetus to pass through during vaginal delivery.

Buried Penis A minor *congenital* defect attributable to a short suspensory ligament within the abdomen which causes the shaft of the *penis* to withdraw into the body. Buried Penis is considered by some to be a *contra-indication* to *neonatal circumcision*.

Buttonhole Circumcision (See photo.) A practice of certain cultural groups (such as the Kikuyu of Kenya) in which a transverse cut is made in the *dorsal* surface of the *foreskin*. The *glans* is then pushed through this slit so that the foreskin rests in the *coronal sulcus* with most of it hanging below the penis. Although being called a *circumcision*, this is not a true *circumcision* since no foreskin is removed.



Buttonhole Circumcision

The resulting large tassel of skin can easily become inflamed due to trauma during masturbation or intercourse. It can also cause trauma to the female partner's genitals.

BXO See *Lichen Sclerosis et Atrophicus*.

Cauterise Apply heat (or silver nitrate or other chemical) to clean a wound and/or stop bleeding.

Cavalier *Uncircumcised*.

The term is mainly used by British schoolboys and is derived from the decorated headgear worn by the Royalists (Cavaliers) during the English Civil War (1642–1651). Opposite of *Roundhead*.

Cervix The neck of the *uterus* between it and the *vagina*. (See diagram on Page 28.)

Chituch (Hebrew) The name of the first (excision) stage of Jewish *circumcision*. See also *Periah*, *Metzizah*.

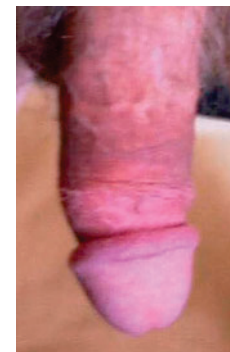Chordee Abnormal downward curvature of the *penis*, sometimes only evident when at least partially erect. In severe cases, considered to be a *contra-indication* to *neonatal circumcision*.

Cicatrice, Cicatrix Scar of a healed wound.

Circumcise "To cut around" (from Latin). The act of surgically removing the *foreskin*.

Circumcised (See photo.) The state of having had a *circumcision*.

Circumcision Minor external surgery to remove the *foreskin*, or *prepuce*, of the *penis*. The unqualified term is properly applied only in relation to the male penis and foreskin, but can also be applied to removal of the analogous female tissue, i.e. the *clitoral hood*.



Circumcised

It is performed for religious or cultural reasons in some communities but primarily for medical reasons such as

improved hygiene and sexual pleasure, as well as the prevention or elimination of problems such as *phimosis*, *paraphimosis* and *balanitis*.

Circumcision may be performed at any age but is best, and most often, done *neonatally* when it is quick, simple, cheap and almost painless.

A properly performed circumcision leaves the *glans* permanently and completely exposed at all times.

Circumcision Scar The scar left after the healing fusion of *shaft skin* and inner *foreskin*. It may differ in pigmentation and/or texture from the surrounding skin.

Clip and Wear Device See *Fit and Wear Device*.

Clipcock Slang term for *circumcised* used from 1661 in records of the London East India Company. Opposite of *Peelcock*.

Clitoral Hood A fibrous covering to the *clitoris* which is the exact equivalent of the male *foreskin*, having developed from the same initial tissue structure. Like the male foreskin it can sometimes be too thick or long to retract during sexual excitement and therefore can prevent the stimulus to the clitoris needed for *orgasm*. It can be trimmed or removed by true *female circumcision* to enable proper stimulation of the clitoris.

Clitoris A small organ in the female genitals which is the exact equivalent of the male *penis*, having developed from the same initial tissue structure. Like the penis it is a primary organ of sexual pleasure. However, unlike the penis, neither *urine* nor sexual fluids are voided through it.

Coitus (Latin) Sexual union; intercourse.

Coitus Interruptus Withdrawal from sexual union before *ejaculation*, in an attempt (often unsuccessful) to avoid pregnancy.

Congenital Defect A birth defect. A foetal malformation that is not (or primarily not) genetic in origin. See also *Genetic Defect*.

Contra-Indication There are a number of possible birth defects (some *congenital*, some *genetic*). It is recommended that *circumcision* should not be performed on a boy suffering from one or more of these problems. These medical conditions are termed 'contra-indications' to *neonatal* circumcision.

Corona, Coronal Rim The flared rim at the back of the *glans*. (See diagram on Page 27.) This is the most sexually sensitive part of the *penis*. After *circumcision* it is common for the corona to expand to a diameter significantly greater than that of the penile shaft. Circumcision allows full stimulation of the corona during sexual activity. The permanently exposed corona also increases the stimulation of the female partner.

Coronal Sulcus The 'groove' behind the *corona* at the back of the *glans*. (See diagram on Page 27.) The sulcus is liable to collect a significant amount of *smegma* in the *uncircumcised* penis.

Surgical Knot A surgical knot is a double knot made with *suture* material such that it will not slip or come untied.

Suture A surgical stitch. Suture material is designed to be very strong whilst being tolerated well by the body. There are two types of suture material: a self dissolving (or soluble) one which allows the stitch to come out in about a week; and a non absorbable type that is used where the stitch needs to hold for longer periods and then has to be removed by the doctor.

Note that 'soluble' sutures are not dissolved by water but only by enzymes from the body. Since these enzymes are sometimes not very plentiful at the surface, soluble sutures are best removed 10 – 12 days after circumcision to avoid the possibility of *stitch tunnels*.

Synechia During development in the womb the *foreskin* is not differentiated from the *glans* penis until a late stage. At birth the foreskin is thus usually still attached to the underlying glans by tissues commonly known as 'adhesions' but more correctly called *synechia*.

These *synechia* can be broken down by a doctor with a blunt probe, as is necessary before infant *circumcision*, but are otherwise normally best left during infancy to resolve themselves. There should, however, be no *synechia* remaining by the time a boy reaches the age of 5, at which time he should be taught to retract his own foreskin daily for washing and every time he urinates. Any *synechia* still remaining by the age of 8 must be broken down to allow proper development and hygiene of the *penis*.

Tanner Stages A method for describing and classifying the progress of puberty.

The five Tanner Stages are well described and illustrated in the 'Glossary and Anatomy' section of the *Circlist web site*

Taylor's Ridged Band See *Frenar Band*. So called after Dr Taylor who 'discovered' it at the tip of the foreskin when examining a handful of dead bodies.

Testicle, Testis The soft egg-shaped organs, consisting primarily of tightly coiled tubes, lying in the *scrotum*, in which sperm are generated and which also produce male hormones, primarily *testosterone*. Plural is testicles or testes. (See diagram on Page 28.)

Testosterone The hormone secreted by the *testes* which sets off male *puberty* and maintains male physical characteristics, including male sexual aggression.

Therapeutic Something done to cure a disease or adverse condition after it occurs – a healing treatment. (Associated noun: Therapy.) See also *Prophylactic*.

Tight When describing the result of a *circumcision*, is one which leaves no significant movement of the shaft skin possible, even when *flaccid*. This is the condition generally preferred by most men seeking *elective* circumcision. See also *Loose*.

Contrary to the claims of some anti-circumcision activists, smegma has no lubricating function (that is done by body oils) and no antibacterial properties.

Snip This term can refer to *circumcision* or *vasectomy* and must therefore be interpreted according to its context.

Sperm (Greek for 'seed'). The abbreviation for spermatozoon (singular) or spermatozoa (plural). These are the very small tadpole-like male seed with an oval-shaped head, a central portion and a long tail, which is capable of forming a baby when it penetrates an *ovum*, a female egg.

A sperm contains the father's contribution of half the genetic material which sets the characteristics of the child, the other half being supplied from the egg. Sperm are made in the *testicles* of men and stored in the *epididymis* until *ejaculated* at *orgasm*, as a component of *semen*. Many millions are produced over a lifetime, but the number is not fixed and the testicles can continue to produce them into old age; men in their 80s have successfully fathered children.

Sphincter The muscles which run around and control the opening of a body orifice or internal structure. The anus has a powerful sphincter muscle; so have the bladder and stomach.

Stenosis Narrowing, contraction or stricture of a passage or duct, such as an artery, or an opening, such as the *meatus* of the *penis*.

Stitch The common name for the medical term *suture*.

Stitch Tunnel (Suture Tunnel) An occasional complication of *circumcision* in which 'tunnels' remain in the skin from where *sutures* had been. They are normally caused when the skin around a suture heals very quickly without the suture having first dissolved or been removed. The pockets formed by the two layers of skin tend to collect dirt and can be susceptible to infection. The skin on the outside of the tunnel can easily be cut off under *topical* or local anaesthetic so as to remove the blemish.

Removing 'soluble' sutures after 10 – 12 days instead of waiting for them to self-dissolve significantly reduces the risk of these tunnels.

Stretching The practice of non-surgical '*restoration*' of the *foreskin* through longitudinal stretching over a considerable period of time. (See *Restoration*).

Sub-incision To cut underneath, especially to open the urethra on the under-side of the penis, thus creating an artificial *hypospadias*. A cultural practice of a small number of tribes, especially amongst the Australian Aboriginal people.

Sulcus A groove or furrow. More specifically the *Coronal Sulcus*. (See *diagram on Page 27*.)

Sünnet (Turkish) *Circumcision*.

Sünnetçi (Turkish) *Circumciser*.

Supercision, Super-incision To cut above, especially a *dorsal* slit in the *foreskin*.

Corpora Cavernosa Two of the three bodies of spongy tissue which, side by side, form the main structure of the *penis* shaft. (See *diagrams on Pages 27 & 28*.) They divide at the base and are attached to the pubic bone. An erection results when these and the *corpus spongiosum* fill with blood.

Corpus Spongiosum The third mass of spongy tissue, through which the *urethra* passes and which forms the structure of the *glans* and the *ventral* part of the *penis*. (See *diagram on Page 27*.)

Cowper's Gland One of several *glands* supplying fluids which make up *semen*. (See *diagram on Page 28*.)

Cryptorchism, Cryptorchidism The medical term for undescended *testicle(s)*. The condition can be 'unilateral' (only one testicle affected, more commonly the right side, with the other descended normally) or 'bilateral' (both sides affected).

Bilateral cryptorchidism is regarded as a *contra-indication* to *neonatal circumcision* because it can indicate an intersex condition.

Cunnilingus Oral sex, applying the tongue to the female external genital organs.

Cunt A slang term for the external female genital organs.

Cut *Circumcised*.

Deep Fascia See *Buck's Fascia*.

Dildo An artificial penis.

Distal A medical term meaning 'relatively further from'. When applied to the penis it means further from the body. Opposite of *Proximal*.

Dorsal A medical term meaning 'on the upper surface' or 'in the upper part'. Opposite of *Ventral*.

Dorsal Nerves The primary nerves serving the *penis*. (See *diagram on Page 27*.)

Dorsal Penile Nerve Block (DPNB) A method of administering local anaesthetic for *circumcision* by injecting it in the vicinity of the two *dorsal nerves*.

Dorsal Slit A cut made along the upper surface of the *foreskin*. This is often a preliminary stage to *circumcision* in order to gain access, particularly in cases of *phimosis*.

In some cultures only a dorsal slit is performed, resulting in a flap of foreskin left hanging down under the glans. Although often referred to as *circumcision*, this is not a true *circumcision* since no foreskin is removed.

Dydoe A piercing of the glans rim, parallel with the penis shaft, usually at the side and symmetrical with a similar piercing on the other side, each to hold a *bar-bell*.

-ectomy A word ending meaning 'removal of', e.g. *appendectomy* = removal of the appendix.

Edema American spelling of *oedema*.

Ejaculation At *orgasm* in the male, semen is shot out of the penis under pressure.

Elective Surgery Surgery done as a matter of choice rather than of necessity.

EMLA™ Cream A widely available *topical* anaesthetic, obtainable without prescription in many countries. It contains two active ingredients, lidocaine and prilocaine. Each gram of cream contains 25 mg of lidocaine and 25 mg of prilocaine.

Enuresis Inability to control urination, urinary incontinence, 'bed-wetting'.

Epididymis A small structure attached to the surface of the *testes*, composed of a mass of small, convoluted tubes that collect the *semen* from the testes and eventually take it down to the *vas deferens*. The name derives from two Greek words meaning 'on top of the twins', since the epididymis sits on and behind each of the testes. (See diagram on Page 28.)

Epispadias A rare birth defect in which the *urethra* opens onto the dorsal (upper) side of the *glans* or onto the *shaft* of the *penis* instead of at the tip of the glans.

A boy with epispadias should not be *circumcised* until after the epispadias has been assessed by a *urologist* and any corrective action taken. This is because tissue from the *foreskin* is commonly used in the repair. The urologist will usually complete the circumcision at the end of the repair operation. See also *Hypospadias*.

Epithelioma A skin cancer.

Epithelium Non-vascular (bloodless) cell tissue which forms the outer layer of the *mucous membrane*; epithelialization is the process of becoming like epithelium. Contrast *mucous membrane*.

Erect The state of the *penis* when sexually aroused. Erection is achieved by engorgement of the tissues of the penis with blood, resulting in the penis lengthening and becoming stiff to facilitate intercourse. See also *Flaccid*.

Erogenous Particularly sensitive to physical sexual stimulation.

Eschar A dry slough resulting from the destruction of living tissue, by gangrene, burn, or caustic action.

Fallopian Tubes A pair of narrow tubes in the female that carry *ova* (eggs) from the *ovaries* to the *uterus*. (See diagram on Page 28.) *Sperm* travels into the fallopian tubes to fertilize the *ova*.

Fellatio Oral stimulation of the *penis*.

Female Circumcision Removal of the hood of the *clitoris*. This is directly analogous to male circumcision and is performed medically when the clitoral hood is too thick or long and inhibits stimulation of the clitoris during intercourse.

The term was incorrectly applied by some early anthropologists (and is still mis-applied to this day) to the complete removal of the female sexual parts which is properly described as *Female Genital Mutilation*.

Female Genital Mutilation (FGM) A procedure carried out in a few areas of Africa and the Middle East in which the female genitals are drastically modified by removal of the whole *clitoris* together with the inner and outer labia. It is often

Self-Abuse *Masturbation*. So called because the Victorians considered it caused various illnesses and adverse conditions. Some folk still do so today!

Semen The whitish, slightly sticky fluid containing *sperm* from the *testicles* and secretions from the *prostate*, the *seminal vesicles*, and possibly from other smaller glands. At *orgasm* semen is *ejaculated* under pressure. Usually, after two days continence, between 2–6 ml (0.07 to 0.21 fl oz) is ejaculated; more frequent ejaculation diminishes this volume.

Seminal Vesicles These provide the bulk of fluid in the *semen*; there are two, placed on each side between the base of the *bladder* and the *rectum*; each is a tube about 2 inches (5 cm), coiled upon itself like a spring, from which bulge several little chambers, the lower end of this tube narrows and joins the *vas deferens*; together they form the ejaculatory ducts which conduct the semen into the *urethra* and thence, as ejaculation occurs, along the *penis*. (See diagram on Page 28.)

Shaft The main length of the *penis* between the abdomen and the *glans*. It is composed of three cylinders of erectile tissue called the *corpora cavernosa* and the *corpus spongiosum*, the latter of which expands at the end to become the glans. The *urethra* passes through the corpus spongiosum. (See diagrams on Pages 26 & 27.)

Shaft Skin The part of the penile sheath that covers the *shaft* from the abdomen to the *foreskin* or *circumcision* scar. It is highly mobile with respect to the underlying structures, being separated from them by the *Buck's Fascia*. (See diagram on Page 27.)

Skin Bridge An occasional complication of *circumcision* (particularly in infants) in which part of the remaining skin heals by attaching to the *glans*, forming a 'bridge' of skin. A skin bridge is the result of an incomplete circumcision in which too little foreskin has been removed; as well as failure to regularly ease the *foreskin* remnant away from the glans and use a non-stick ointment (like Vaseline) during the early stages of healing.

Skin bridges should be treated as soon as possible after the main circumcision has completely healed by cutting through them under local anaesthetic.



Smart Klamp™

Smart Klamp™ (See photo.) One of the many *circumcision* aids which fall into the category of *Fit and Wear* devices.

Smegma (From Greek – 'soap'). A white cheese-like substance with a distinctive stale and offensive smell, which collects in the *coronal sulcus* and under the *foreskin* of the *uncircumcised*. It is composed of excess lubricant from the *Tyson's Glands*, sweat, stale urine, dead skin cells and collected debris.

If not cleaned away at least daily, smegma can become a breeding ground for bacterial, fungal or viral infections which turn it yellow and cause it to smell significantly. The bacteria, etc can cause *balanitis* as well as contributing to other more serious diseases of the *penis*.

Retained smegma has been implicated in genital cancers.

Recircumcision surgery is always more difficult than performing an original circumcision and patients should only use a surgeon who is experienced in performing re-circumcisions to the patient's requirements.

It should be noted that, since the old scar line must of necessity be removed, the result of a revision always includes both tightening of the skin and also removal of some more of the former inner layer, thus giving a 'lower' scar line.

Rectum The final section of the large intestine, ending at the *anus*. (See diagrams on Page 28.)

Redundant Prepuce A *foreskin* that more than covers the *glans* when the penis is *flaccid*.

Restoration Restoring the coverage of the *glans* through either surgical or non-surgical means. The restoration process is long and complicated and the restored '*foreskin*' has few of the attributes of the original except that it very loosely covers the *glans* to a greater or lesser extent – better described as a 'faux skin'.

A very small number of *circumcised* men blame their lack of self-esteem on their *circumcision* and believe that if they can only get back their *foreskin* all will be well with them. They thus 'restore' their *foreskin* by stretching it longitudinally over a considerable period of time. Because their disorder is psychological rather than physical the presence of a semblance of a *foreskin* satisfies their desires and they claim increased sexual pleasure.

Ridged Band See *frenar band*.

Ring Block A method of administering local anaesthetic for *circumcision* by injecting it in in a ring around the base of the *penis*.

Roundhead *Circumcised*.

The term is mainly used by British schoolboys and is derived from the rounded helmets with rims worn by the Parliamentarians (Roundheads) during the English Civil War (1642–1651). Opposite of *Cavalier*.

Sack Slang term for the *scrotum*.

Sandek (Hebrew) The sponsor or godfather who holds the boy on his lap during a Jewish *circumcision*.

Scar Line The line where the mucosal skin remaining from the inner layer of the *foreskin* meets the outer skin on the shaft of the *penis* following *circumcision*. This may be anywhere from immediately behind the *coronal sulcus* to several centimetres back along the shaft. The actual surgical scar is usually hard to see but its location is often marked by a distinct colour change between the darker shaft skin and the lighter former inner layer of the *foreskin*.

Scrotum The pouch behind the *penis* which houses the *testicles*. The scrotum lengthens and contracts with changes of temperature so as to keep the testicles at as constant a temperature as possible. (See diagram on Page 28.)

followed by infibulation – sewing together of the cut surfaces. The sole purpose of this activity is to prevent sexual pleasure in women.

It was incorrectly called female circumcision by some early anthropologists and this term is now eagerly used by the opponents of male circumcision to confuse the issue and attempt, by analogy, to discredit male circumcision.

Fistula A pipe-like channel. Usually referring to an unusual or unwanted opening into the body.

Fit and Wear Device Any of a class of *circumcision* devices which act by occluding the blood supply from the *foreskin*, which soon dies and falls off. These devices generally clamp the *foreskin* between two layers of tough plastic to achieve the occlusion. They are worn for the week or two that it takes for the *foreskin* to die.

Typical devices are: Ali's Clamp™, *Smart Klamp*™, Sunathrone Clamp™ and Tara KLamp™.

The *Plastibell*™ and *Circumplast*™ also fall into this class although occlusion is obtained by tying a string over the *foreskin* into a groove in the bell rather than by plastic to plastic clamping.

For more information see the 'Instruments and Techniques' section of the *Circlist web site*.

Flaccid The normal, relaxed state of the *penis*, indicating that the male is not sexually aroused. See also *Erect*.

Fold The end of the *uncircumcised* penis, where the outer skin folds inward and forms the moist mucosal area of the inner *foreskin*.

Forceps A surgical instrument designed to hold and grip tissue. In *circumcision* sometimes used to grip the *foreskin* and guide the scalpel.

Forceps Guided A *circumcision* technique in which the *foreskin* is pulled forward of the *glans* and a pair of *forceps* is clamped across it in front of the *glans*. A scalpel is then used to remove the *foreskin*. The resulting cut edges then normally require to be stitched to complete the *circumcision*. It is the medical equivalent of the traditional Jewish method. See also *Barzel*.

For more information see the 'Instruments and Techniques' section of the *Circlist web site*.

Foreskin (Also known as the *Prepuce*). The part of the skin system of the *penis* covering the *glans*. (See diagrams on Pages 26 & 28.) This is composed of two layers. The outer skin, which is contiguous with – and identical to – the shaft skin, folds inward at the end of the *foreskin*. From this *fold* to where it joins behind the *glans* is the moist *mucosal* area of the inner layer.

During *erection*, the normal *foreskin* rolls back on itself exposing the whole *glans*.

The *foreskin* is a remnant of earlier stages of evolution (much as the appendix is) where it was necessary to protect the *glans* from abrasion from undergrowth and

tree branches. Now that man travels on two legs rather than four and is generally clothed the foreskin serves no further significant purpose.

The presence of a foreskin can lead to *phimosis*, *paraphimosis*, *balanitis*, urethritis, retained *smegma*, a higher risk for penile and cervical cancer, and a higher risk for sexually transmitted diseases including HIV/AIDS.

The foreskin should become fully, freely and painlessly retractable by at least 8 years old and medical intervention should be sought by parents if this is not the case.

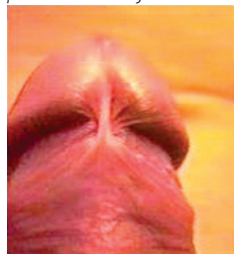
Fossa Navicularis (Latin) Where the final section of the *urethra* widens a little for about the length of the *glans* before narrowing again at the *meatus*.

Frenar Band Elastic tissue at the *fold* of the *foreskin* (between the inner and outer foreskin) that serves only to contract the tip of the non-retracted foreskin causing it to remain positioned over the *glans* and prevent ingress of dirt, etc..

Phimosis is caused when this ring closes too tightly and thus does not allow free passage of urine, or free and full retraction of the foreskin.

Frenectomy, Frenulectomy Removal of the *frenulum*. This can be a stand-alone procedure to correct *frenulum breve*. It should normally also be performed as part of a complete *circumcision*.

Frenulum (also called Frenum or Frænum) (See photo on left and also the diagram on Page 26.) A fibrous cord of connecting tissue on the underside of the *penis* which joins the *glans* to the inner *foreskin* (much like the frenum of the



Frenulum

tongue). The sole purpose of the frenulum is to assist the foreskin to re-cover the *glans* as an erection subsides.

Frictional trauma and accidental wounds cause fissures, tearing, destruction or localized areas of damage.

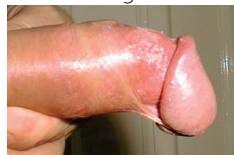Post-coital erosion of the frenulum is not uncommon.

The frenulum contains a small artery and trauma to it can result in very significant bleeding. It is generally recommended that the frenulum be removed during *circumcision*.

The sexually sensitive nerves in this area are under the frenulum rather than in it; so removal has no adverse effect on sexual sensitivity, but may actually enhance it.

Frenulum Breve The condition in which the *frenulum* is very short and tight.

A frenulum breve prevents the normal complete retraction of the *foreskin* and may distort the *glans* downwards during erection (see photo); it thus inhibits normal sexual activity. In some cases it can lead to impotence as the sufferer suppresses erections due to the pain they cause.



Frenulum Breve

A short frenulum can rip during sexual activity with painful, very bloody and highly embarrassing consequences.

Priapism Persistent erection of the *penis*. Priapus was the Greek and Roman god of procreation, and hence of gardens, vineyards etc, depicted as having a disproportionately large *phallus* in statuettes often placed to warn off garden predators or as a scarecrow.

Prince Albert A ring worn in the *glans* which enters through the *meatus* and emerges via a piercing on the under side of the *penis* close to the *frenulum*.

Prophylactic Something done to prevent disease before it occurs – a preventative treatment. (Associated noun: Prophylaxis.) See also *Therapeutic*.

The majority of *circumcisions* (especially in infancy) are prophylactic with only a minority being *therapeutic*.

Prostate A *gland* at the opening of the *bladder* into the *urethra* in the male. In the adult human it is about 4 cm across, about the size of a large chestnut; composed of muscular and glandular tissue, it secretes fluids into the *urethra* to form *semen*. (See diagram on Page 28.)

Its growth in older men may result in difficult urination. The prostate is also a frequent location for cancer. These can be cured by *prostatectomy*.

Prostatectomy A procedure cutting away some (or all) of the *prostate* gland. Often by passing an instrument down the *urethra*.

Proximal A medical term meaning 'relatively closer to'. When applied to the penis it means closer to the body. See also *Distal*.

Puberty The state or condition of having become functionally capable of producing offspring. In England the age of reaching puberty is legally defined as being 14 in boys and 12 in girls, but individuals differ in the age at which they actually reach this condition.

Puberty Phimosis A *phimosis* which develops as the *penis* grows significantly at *puberty*, although prior to this the *foreskin* may have been able to be freely retracted. Puberty phimosis is particularly likely where the foreskin is long or earlier retraction has not been encouraged. It will not cure itself and will most likely lead to *paraphimosis*. *Circumcision* is thus strongly recommended as soon as the phimosis is discovered.

Pubes Pubic hair.

Pubic Of the pubis, the area at the front of the pelvis, the bone-structure that joins hips and back-bone.

Raphé (Pronounced 'raff-A'). The line of union of any two contiguous, bilaterally symmetrical structures. In the context of the male genitalia, the Raphé runs down the center of the *scrotum* and across the *perineum* to the *anus*.

Recircumcision, Revision A second or subsequent operation to tighten or otherwise change the appearance of a *circumcised penis* or to correct an error in the original *circumcision*.

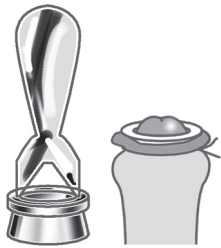The foreskin of an infant may be bonded to the *glans* by *synechia* (adhesions) and thus inability to retract the foreskin in boys under 5 years old is not in itself an indication of *phimosis*. In the older child, teenager or adult, *phimosis* is present if the foreskin cannot be freely, easily and painlessly retracted to uncover the whole *glans* and *coronal sulcus* both when *flaccid* and when *erect*.

The only sure, reliable, immediate and permanent cure for *phimosis* is *circumcision*.

Phimotic Pertaining to *phimosis*.

Pillcock See *peelcock*. (19th century English; probably the origin of the abusive term 'pillcock'.)

Plastibell™ (See *Photo*.) A *circumcision* device in the form of a small plastic bell which is placed over the *glans*. The *foreskin* is pulled over the bell and a thread is tied tightly to compress the foreskin into a groove near the rim of the bell. This results in the blood supply being cut off from the foreskin which dies in about a week. The foreskin and bell fall off leaving a neatly healed result which requires no stitching. The Plastibell™ can only be used on pre-pubescent boys and is not made in large sizes.



Plastibell™

For more information see the 'Instruments and Techniques' section of the *Circlist web site*.

-plasty A word ending meaning 'repair of', e.g. *frenuloplasty* = repair of a torn *frenulum*.

Posterior Towards the rear. Opposite of *Anterior*.

Posthitis Inflammation of the *foreskin*. See also *Balanitis* and *Balanoposthitis*.

Premature Withdrawal See *Coitus Interruptus*.

Prepuce A more formal name for the *Foreskin*.

Preputial Opening The narrow opening at the tip of the *foreskin*. (See *diagram on Page 26*.) *Phimosis* exists if this is too narrow and tight to allow free exit of *urine*, without *ballooning*; or to allow free and full retraction of the foreskin whether *flaccid* or *erect*.

Preputioplasty A method of relieving a *phimosis* by surgically widening the opening at the tip of the *foreskin*.

There are several methods but the most common involves making a longitudinal cut through the tight *phimotic* tissue. The sides are then pulled outwards so that the cut lies transversely at which point the edges are sewn together again.

A preputioplasty will relieve *phimosis* at the time it is performed, but the cut may later toughen and cause a fresh *phimosis* to form. It is therefore a poor substitute for *circumcision*.

To cure *frenulum breve*, the *frenulum* can be removed as a stand-alone procedure (*frenectomy*) or as part of a *circumcision*.

Genetic Defect A physical defect or medical condition that is inherited, e.g. *haemophilia*. See also *Congenital Defect*.

Gland, Glands These are organs of the body which produce hormones (eg the thyroid gland), fluids for use in the body (eg the lymph glands) or, for example, pre-ejaculate and additive parts of semen (eg *Cowper's gland*).

Be careful not to confuse glands with the *glans*.

Glans The bulbous head of the *penis*, which is structurally part of the *corpus spongiosum*. (See *diagrams on Pages 26 & 28*.) It is the primary area of sexual sensitivity and stimulation.

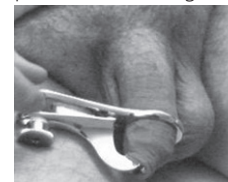The name comes from the latin for 'acorn', referring to the shape of the *glans*. It has many slang names such as: bell-end, cock-head, helmet and knob.

In the *uncircumcised*, the *glans* is generally covered by *foreskin* when the penis is *flaccid* although the amount of this covering varies, from man to man, between 'complete coverage with significant overhang' to 'no coverage at all'.

During *erection* the foreskin should slide back to completely uncover the *glans*, allowing it to be fully stimulated, but often the foreskin is too tight or long and fails to fully retract (*phimosis*). *Circumcision* permanently bares the *glans*, thus always allowing full stimulation for both partners during sex.

Although ending with an 's', *glans* is singular. Be careful not to confuse the *glans* with *glands* as it does not produce anything of its own.

Gomco™ Clamp (See *photo*.) An aid to *circumcision* in which a metal bell is placed over the *glans* to protect it and the *foreskin* is pulled up over it. A clamping plate then holds the foreskin in position whilst the desired amount is cut off with a scalpel, using the plate as a guide. The resulting pair of cut edges then require stitching (except in some young infants) to complete the *circumcision*.



Gomco™ Clamp in use

For more information see the 'Instruments and Techniques' section of the *Circlist web site*.

Gonads See *Testes*.

Guiche (Pronounced 'geesh') A piercing in the skin of the *perineum* just behind the *scrotum*, in which a ring or other object is worn.

Gynaecologist A doctor specialising in the female reproductive organs. Many are also *obstetricians* as the specialities overlap to some extent.

Gynaecomastia A non-cancerous increase in the size of breast tissue in males. Up to 70% of adolescent boys have some breast development during *puberty*. Newborn and adolescent males often experience temporary *gynecomastia* due

to the influence of maternal hormones and hormonal changes during puberty, respectively.

The condition is usually temporary and resolves itself as the boy grows older. Extreme cases can be treated by surgery.

Hæmatoma A collection of blood beneath the skin, forming a bruise or 'blood-blister'.

Hæmophilia An inherited medical condition, affecting only males, in which the sufferer's blood does not clot properly due to a *genetic defect*. (Women carry the defective gene without showing the symptoms of hæmophilia).

Hæmophilic A male whose blood does not clot properly due to *hæmophilia*. Conventional surgery on a hæmophilic can result in considerable loss of blood and is thus to be avoided as far as possible. *Circumcision* is still possible using a laser which seals the blood vessels as it cuts, thus causing less bleeding and general trauma. The advice of a hæmatologist should always be sought before a hæmophilic is circumcised.

Hæmorrhage Bleeding from a severed blood vessel, especially when profuse or dangerous.

Hæmostasis (noun) Prevention of bleeding.

Hæmostat Locking *forceps* used to hold closed a bleeding vessel.

Hæmostatic (adjective) Stopping *hæmorrhage*.

Hafada (Arabic) A piercing in the skin of the *scrotum* at the side near the base of the *penis*, in which a ring or *bar-bell* is worn. (A practice of Arabic origin).

Hakim (Arabic) Doctor.

Helmet Slang for the *glans*, so called from its resemblance to a fireman's helmet.

Hidden Penis See *Buried Penis*.

High When used to describe the position of the *circumcision* scar line, this is taken to mean closer to the base of the penis and further from the *glans*. This preserves much of the former inner foreskin. See also *Low*.

Hooded Foreskin, Hooded Prepuce Incomplete circumferential formation of *foreskin* with a *dorsal* component (the dorsal hood) present but an absent or incomplete *ventral* portion. Typically seen in boys with *hypospadias* or isolated *chordee*. Surgical correction of *hypospadias* and the much rarer condition *epispadias* both commonly require the harvesting of the remaining foreskin as donor tissue for the repair process. In other cases of hooded prepuce the uneven cosmetic appearance can easily be corrected by *elective circumcision*.

Hydrocele (Pronounced 'hydro-seal') A tumour with a collection of fluid, especially one located in the cavity of the *tunica vaginalis* of the *testis*; a swelling of the testicle from which clear or cloudy fluid can be drawn.

Pearly Penile Papules (PPP) In essence these are swollen hair follicles without the hair, located on the *corona* and found in approximately 30% of men at some time in their adult lives. They are benign and do not warrant treatment, but to the untrained eye can be confused with genital warts. Being located on the *glans*, they are unaffected by *circumcision*. If you have them, it is worth a discussion with your doctor to ensure that they really are benign papules and not something more serious.

Pee, Piss Slang terms for *urine*, or urination.

Peelcock *Uncircumcised*. (19th century English.) Opposite of *clipcock*, and of the same origin.

Penile Of or relating to the *penis*.

Penile Reduction Surgery A derogatory and inaccurate term for *circumcision* devised by those opposed to it in order to try to discredit it. Circumcision does not reduce the *penis* itself in any way, but only removes the *foreskin* covering the *glans*.

Penis The male organ of sexual intercourse. It is also the organ through which *urine* is passed. (See *diagrams on Pages 26 & 28*.)

It is made up of three bodies of *corpora cavernosa* and *corpus spongiosum*, covered with skin. It is very variable in size with normal adult length ranges between 2.9 to 4.5 inches (72 to 115 mm) flaccid and 4.4 to 8.3 inches (122 mm) erect. The circumference ranges between 3 to 4.5 inches (75 to 105 mm) flaccid and 3.4 to 4.8 inches (85 to 120 mm) erect.

There are numerous slang terms for the penis, including: *cock, dick, dong, junk, John Thomas, Peter, prick, wang, willy and yard*.

Periah (Hebrew) The second main stage of Jewish *circumcision*, when the operator puts his two thumb-nails under the membrane of inner *foreskin* and tears it down the centre until the edge of the *corona* is exposed. See also *chituch, metzizah*.

Perineum The area of skin between the back of the *scrotum* and the *anus*. A central line called the median *raphé* is evident running across the perineum and onto the scrotum. The perineum is sometimes pierced to insert a *guiche*.

-pexy A word ending meaning 'fastening of', e.g. orchidopexy = fastening an errant testicle into the scrotum.

Phallus (Greek) The penis. Also used for an image of the male generative organ, symbolizing the generative power in nature, venerated in various religious systems (hence phallic worship); also the name for a genus of fungi, including the common stinkhorn, because of their shape, and of other vertical penis-like objects. (Adjective = phallic).

Phimosis A condition in which the *foreskin* is too tight. If *ballooning* of the foreskin occurs during urination at any age then a phimosis exists.

Mohel (Hebrew) A Jewish ritual circumciser. Often, but not necessarily, a doctor, but always fully trained and certified in both the religious and medical aspects of ritual infant *circumcision*. The plural of mohel is mohelim.

Mucosa, Mucous Membrane Moist and sensitive type of skin which secretes mucus, a slimy fluid, and lines various tubular cavities of the body such as the nose and mouth, the *urethra* and the *foreskin*. (Compare *epithelium*.)

Mutual Masturbation Sexual activity in which the two participants masturbate one another, usually simultaneously.

Nads Slang abbreviation for *Gonads*. The *testicles*.

Necrosis Mortification; the death of a piece of tissue (as in *circumcision* using *Fit and Wear* devices). See also *atrophy*.

Neonatal Soon after birth. Newborn.

Obstetrician A doctor specialising in pregnancy, childbirth, and the postpartum period. Many are also *gynaecologists* as the two specialities overlap to some extent.

Oedema A swelling due to watery fluid collecting in the intercellular spaces of connective tissue. Adjective = oedematous.

Oetang (or Oelang) A piercing in the edge of the foreskin in which a large-diameter ring is worn to demonstrate sexual continence, originally in Borneo.

Onanism See *Masturbation*. In the Biblical account, Onan displeased God by "spilling his seed on the ground"; although he probably actually practiced *coitus interruptus* rather than masturbation.

Orgasm The climax of sexual excitement. In the mature male, *ejaculation* occurs, then the erection of the penis begins to subside. In both male and female, the height of pleasure is experienced and sexual tensions are released.

Ovary, Ovaries (See *diagram on Page 28*.) The ovaries are two organs that store *ova* (eggs) in a woman's body. Ovaries also produce hormones, including estrogen, progesterone, and testosterone. During puberty, the ovaries start to release ova each month and do so until menopause. Usually, one ovary alternately releases an ovum each month.

Ovum, Ova Female 'eggs'; which are stored in the *ovaries*.

Paraphimosis A condition in which the *foreskin*, having been retracted behind the *glans* (often with some difficulty), is too tight to return to covering the glans. The trapped foreskin causes the glans to swell more and a vicious circle sets in. It is imperative that the swelling of the glans be reduced immediately and the foreskin replaced, otherwise emergency surgical intervention will be necessary to prevent loss of the glans.

Once a paraphimosis has occurred it is almost certain to recur and this should be prevented by *circumcision* as soon as the swelling from the paraphimosis has resolved completely.

Hymen A thin fleshy tissue that stretches across part of the opening to the *vagina*. This is broken during first intercourse if not already broken during physical exertion (such as horse riding). (See *diagram on Page 28*.)

Hypospadias A fairly rare birth defect in which the *urethra* opens onto the under side of the *glans* or the shaft of the *penis* instead of at the tip of the glans.

A boy with hypospadias should not be *circumcised* until after the hypospadias has been assessed by a *urologist* and any corrective action taken. This is because tissue from the *foreskin* is commonly used in the repair. The urologist will usually complete the circumcision at the end of the repair operation. See also *Epispadias*.

Infibulation The fastening of the sexual organs with a fibula (Latin) or clasp to impose sexual abstinence; in males, the foreskin is pierced and a ring fixed in place.

The earliest records are from ancient Greece, where athletes were infibulated to encourage peak performance. Roman actors and singers were infibulated because it was thought that strict sexual abstinence kept the voice pure and young.

In females the inner and/or outer *labia* are cut away (usually with the *clitoris*) and the raw surfaces *sutured* together; when healed this closes the *vulva* except for a small passage for *urine* and menses; an incision is necessary at marriage to permit intercourse and childbirth; the practice, which is widespread in Muslim northern Africa, is widely condemned elsewhere as *female genital mutilation* (FGM).

Informed Consent The legal condition whereby a person can be said to have given consent based upon a clear appreciation and understanding of the facts, implications and future consequences of an action. In order to give informed consent, the individual concerned must have adequate reasoning faculties and be in possession of all relevant facts at the time consent is given. In cases where an individual is considered unable to give informed consent, another person is generally authorized to give consent on his behalf, e.g. the parent(s) or legal guardian(s) of a child.

Intact An inaccurate term used by the opponents of *circumcision* to denote an *uncircumcised* penis.

Intactivist An opponent of circumcision. (From 'intact' and 'activist'.)

-itis A word ending meaning 'inflammation of', e.g. *appendicitis* = inflammation of the appendix.

Japanese Circumcision See *Basal Circumcision*.

Jewish Shield See *Barzel*.

Keratinisation Keratin is an organic substance found in horns or the cornea of the eye; keratinisation is sometimes wrongly used to describe hardening of the skin of the *glans* as it transforms from *mucosa* to *epithelium* following *circumcision*.

Kidneys The organs which remove toxins, urea and excess water from the blood to create *urine*, which is passed to the *bladder* for temporary storage.

The immature kidneys of a baby can easily be permanently damaged by the back pressure of urine unable to escape fast enough from a phimotic foreskin.

Knob A slang term for the *glans* of the *penis*.

Labia Majora The outer lips. (See *diagram on Page 28*.) These are fleshy, covered by pubic hair, and connect to the thighs. Most women have larger outer lips than inner lips, but some women have larger inner lips than outer lips.

Labia Minora The inner lips. (See *diagram on Page 28*.) They cover the opening of the *vagina* and the *urethra*. Inner lips are visible when the *labia majora* are pulled apart. In many women, the inner lips stick out of the outer lips. Inner lips can be short or long, wrinkled or smooth. The inner lips are also sensitive and can swell when a woman is aroused. The inner lips can vary in colour from pink to brownish black depending on the colour of a woman's skin. The inner lips can also change colour as women mature.

Lichen Sclerosus et Atrophicus (Formerly called Balanitis Xerotica Obliterans, or BXO). This is an auto-immune form of *balanitis* resulting in extreme scarring of the *glans*. In common with all auto-immune conditions, it is difficult to treat because the body's natural defence mechanisms are working against the patient's best interests.

Lichen Sclerosus et Atrophicus is almost exclusive to *uncircumcised* males, particularly in the presence of *phimosis*.

Treatment with steroid creams and ointments reduces inflammation and a strong steroid used regularly for approximately three months may enable the skin to return to normal. However, if the condition has been untreated for a long period of time, significantly changing the skin, steroid cream is likely to be less effective and *circumcision* will be required.

Circumcision, by allowing the *glans* to thoroughly dry out, is almost always effective in helping with the cure of this problem. A radically tight style is desirable to ensure total and permanent exposure of the *glans*.

Loose A *circumcision* which leaves significant possible movement of the shaft skin even after erection. See also *Tight*.

Low When used to describe the position of the *circumcision* scar line, this is taken to mean closer to the *glans* and further from the base of the *penis*. A low *circumcision* removes the maximum amount of the former inner layer of foreskin. See also *High*.

Male Genital Mutilation (MGM) A derogatory term for *circumcision*, devised by those opposed to it, in order to try to discredit it by analogy with the extreme forms of *female genital mutilation*.

Man-Boobs See *Gynaecomastia*.

Masturbate, Masturbation To stimulate one's own sexual organs by rubbing, etc. Victorian doctors termed it 'self-abuse' and claimed that masturbation weakened

the sight and/or the mind, or even caused blindness or madness. There is no evidence of any such connection – if there were, most men and women would be blind and/or mad as nearly everyone masturbates at some time.

By providing experience of what gives oneself pleasure, masturbation can pave the way towards enjoyment of sex with a partner. *Circumcision* was once recommended to prevent masturbation. Although it may not do so physically, the operation or its threat may discourage excessive masturbation, but it is as (or more) enjoyable after *circumcision* as before.

Meatal Stenosis An abnormally narrow *meatus*. This condition is most frequently caused by ulceration of the meatus resulting from prolonged contact with stale *urine*. This may be in the diaper (nappy) of an infant or inside a tight foreskin.

If the ulcer is noticed early and properly cared for (usually just by applying Vaseline or other barrier ointment) it heals with no problem, but if it is neglected it can lead to *stenosis*. If *circumcision* is carried out soon after birth, when the urine is very dilute, meatal stenosis is less likely to occur.

Meatitis Inflammation of the *meatus*.

Meatotomy Operation of cutting the *meatus* of the *glans* to widen it. It is usually done either because of difficulty in urinating due to *meatal stenosis*, or to allow an instrument to be inserted, e.g. to inspect the urinary tract.

Meatus (Pronounced 'me-ate-us') The opening of the *urethra* at the tip of the *glans* of the *penis* where *urine* and *semen* exit the body of the male. (See *diagrams on Pages 26 & 28*.)

Occasionally used to also refer to the *preputial opening* at the tip of the *foreskin*.

Metzizah (Hebrew) The third stage of a Jewish *circumcision*, when blood (The Blood of the Covenant) is sucked away. This stage is usually now omitted, except by the ultra-orthodox, to avoid the risk of any infection being accidentally passed from the *mohel* to the infant. See also *chituch*, *periah*.

Micturition Urination. The act of 'passing water'.

Mogen™ Clamp (See *Photo*.) A *circumcision* aid used mainly for infant *circumcision* (particularly in the Jewish community). The clamp has two hinged arms and a locking lever. In use the *foreskin* is pulled forward of the *glans* and clamped, just in front of the *glans*, between the hinged arms of the clamp which are then locked. A scalpel is used to remove the foreskin. The resulting cut edges may require to be stitched to complete the *circumcision*.



Mogen™ Clamp

For more information see the 'Instruments and Techniques' section of the *Circlist web site*.